

## MORPHOLOGICAL FEATURES OF THE SKULL IN THE EURASIAN BROWN BEAR (*Ursus arctos arctos* - Linnaeus, 1758): CASE STUDY

Petronela Mihaela ROȘU, Bogdan GEORGESCU, Cristian Romeo BELU, Letiția PURDOIU,  
Sorina Andreea MIHAI, Eduard GUREȘOAE, Valerica DĂNACU

University of Agronomic Sciences and Veterinary Medicine of Bucharest, 59 Marasti Blvd,  
District 1, Bucharest, Romania

Corresponding author email: [rosupetronelamihaela@yahoo.com](mailto:rosupetronelamihaela@yahoo.com)

### Abstract

*This study aims to analyze and describe the morphological characteristics of the skull in the Eurasian brown bear (Ursus arctos arctos) in Romania. The morphological particularities of the skull are essential elements for the recognition of the species. The data from the literature on the morphology of the skull in this species are insufficient and focused mostly on the morphometric particularities of the skull. For the present study, we examined a skull from an adult bear, that is part of the collection of the Anatomy department. The bear is a protected animal and is hunted only under conditions established by law. The observational analysis of the morphological features of the skull led to the following conclusions: the skull is compact, elongated and relatively narrow on the dorsal part, the zygomatic processes of the frontal bone are very short and lacking in supraorbital foramen, the external sagittal crest is reduced, the lacrimal bone has a single lacrimal foramen, the articular surface for the mandible is represented by a transversal elongated articular cavity, being delimited in an caudal direction by the retroarticular process, the accessory palatine foramina are very small.*

**Key words:** bear, skull, zygomatic process, external sagittal crest.

### INTRODUCTION

The Eurasian brown bear (*Ursus arctos arctos*) (Linnaeus, 1758) belongs to the Order *Fissipeda*, an order that includes carnivorous mammals, belonging to the *Ursidae* Family, Genus *Ursus*. It is a species that lives all over Europe, and in Romania it can be found in the mountainous area (about 6000 specimens), where their number is constantly growing, due to restrictive measures regarding the hunting of this species. (Cotta & Bodea, 1969; Șelaru & Goicea, 2005)

There is a considerable lack of literature regarding the morphological features of the skull in the brown bear, as opposed to morphometric studies, which are far more common. (Yousefi, 2016; Mihaylov et al., 2013). Moreover, data regarding the morphological aspects of skulls in other various species of carnivores has been found. (Atalar et al., 2009; Getty, 1975; Jackson, 2011; König & Liebich, 2004); Movahhedi et al., 2014).

This study was conducted on a skull of a specimen of Eurasian brown bear (*Ursus arctos arctos*), and its aim was to present key particularities based on which the Eurasian

brown bear can be differentiated from other species of carnivores.

Taking into consideration that the number of hunted or captive exemplars in Romania is very low, the morphological particularities of the skull in this species have been scarcely studied.

### MATERIALS AND METHODS

The study material was represented by a Eurasian brown bear skull (*Ursus arctos arctos*), belonging to the collection of the Anatomy department. The most interesting aspects were described and photographed. The description, identification and approval were made in accordance with the 2017 *Nomina Anatomica Veterinaria* (NAV).

### RESULTS AND DISCUSSIONS

In the Eurasian brown bear (*Ursus arctos arctos*), the dorsal surface of the skull is characterized by an elongated and relatively narrow appearance. The nuchal crests are relatively high, reunited in the dorsal median plane, forming a reduced occipital protuberance.

The parietals are convex on the whole surface, the external sagittal crest is short and slightly prominent in the caudal third of the parietal suture, dividing into two very short temporal lines. The zygomatic processes of the frontal bone are very small in size, having a ventro-caudal orientation and lacking of the supraorbital foramen at the base (Figure 1).

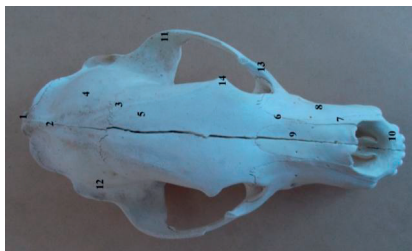


Figure 1. Dorsal face of the skull in Eurasian brown bear (*Ursus arctos arctos*) - 1. External occipital protuberance; 2. External sagittal crest; 3. Temporal line; 4. Parietal bone; 5. Frontal bone; 6. The nasal processes of the frontal bone; 7. The nasal processes of the incisive bone; 8. Maxilla; 9. Nasal bone; 10. The incisive bone; 11. The zygomatic process of the temporal; 12. The temporal bone; 13. The zygomatic bone; 14. The zygomatic process of the frontal

The frontal bones are narrow and elongated, covering almost half of the dorsal face of the skull, ending in the rostral extremity by two narrow and sharp extensions, representing the nasal processes of the frontal bone.

The nasals do not articulate on the sides with the maxilla, they articulate only with the nasal processes of the frontal bone and of the incisive bone, whereas in the rostral extremity, it ends slightly bifid, delimiting a small notch (Figure 2). The lateral surface of the skull of the Eurasian brown bear (*Ursus arctos arctos*) has an incomplete orbit. The zygomatic process of the frontal bone is very short; so it does not join the zygomatic arch.

The temporal fossa is elongated and slightly convex. The orbito-temporal crest is strongly highlighted. The fossa of the lacrimal sac is narrow. The lacrimal duct is delimited by the lacrimal bone and the maxillary bone. At the level of the lacrimal bone, a single lacrimal foramen can be observed (Figure 3).

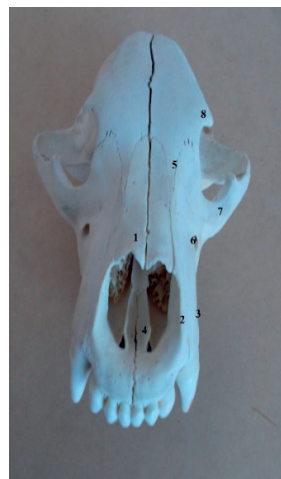

Figure 2. Eurasian brown bear skull (*Ursus arctos arctos*) - dorsal face - 1. Nasal bone; 2. The incisive bone; 3. Maxilla bone; 4. Vomer bone; 5. Nasal processes of the frontal bone; 6. Infraorbital foramen; 7. The zygomatic bone; 8. The zygomatic process of the frontal bone

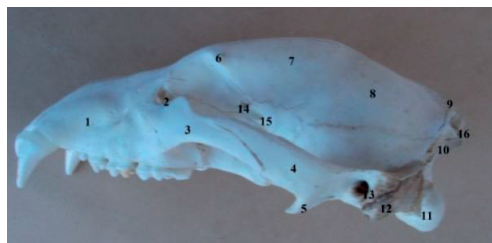

Figure 3. The lateral face of the skull in Eurasian brown bear (*Ursus arctos arctos*) - 1. Maxilla; 2. Lacrimal foramen; 3. Zygomatic bone; 4. The zygomatic process of the temporal; 5. Retroglenoid process; 6. The zygomatic process of the frontal bone; 7. Temporal line; 8. Parietal bone; 9. External sagittal crest; 10. Nuchal crest; 11. Occipital condyle; 12. The mastoid process of the petrous temporal bone; 13. External auditory canal; 14. Ethmoidal foramen; 15. Optic foramen; 16. External occipital protuberance

The maxillary foramen is very wide and elongated in appearance, being located under the fossa of the sac of the lacrimal gland, and communicates with the infraorbital foramen through a short infraorbital duct. Between the maxillary and the lacrimal foramen, we can observe another foramen, possibly of vascular nature (Figure 4).

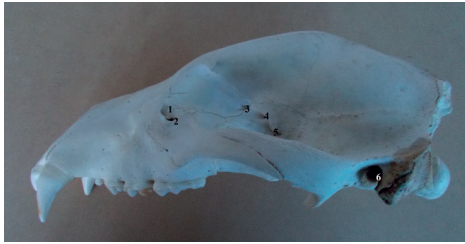


Figure 4. The lateral surface of the skull in Eurasian brown bear (*Ursus arctos arctos*) - 1. Lacrimal foramen; 2. Vascular foramen; 3. Ethmoidal foramen; 4. Optic foramen; 5. Orbital fissure; 6. External auditory canal

In the caudal extremity of the maxilla, behind the tubercle and under the maxillary foramen, there are two other foramina, the sphenopalatine foramen and the caudal palatine foramen, separated by a small bony blade arranged transversely, thus giving the area a layered appearance.

On the lateral face of the maxilla, an infra-orbital foramen can be seen, extended in the rostral direction by a small fossa. The zygomatic process of the maxilla is arranged ventromedial in the rostral part of the zygomatic arch, being articulated with the lacrimal bone under the maxillary foramen. The zygomatic bone has two processes: one of them being located in the reduced rostrum and another long one, situated in a latero-caudal position.

The zygomatic process of the temporal situated in a latero-rostral position, presents ventrally an elongated latero-medial, deep glenoid cavity, behind which there is a prominent retroglenoid process (Figure 5).

The tympanic bulla is reduced and the muscle process is short. The mastoid process of the temporal petrous part is well developed and is located between the temporal and occipital squamous parts.

The external auditory canal is considerably highlighted. Behind and at the base of the retroarticular process is located the retro-articular foramen. The stylomastoid foramen is located behind the external auditory canal.

At the level of the orbital hiatus, the ethmoidal foramen, the optic foramen, the orbital fissure, the foramen rotundum and the rostral alar foramen open together, being separated by a bony blade arranged transversely (Figure 6). At the level of the pterygoid process of the sphenoid, can be seen the arrangement of the alar canal, through which the anterior alar

foramen communicates with the posterior alar foramen. Behind the caudal opening of the alar canal, the *foramen ovale* can be observed.

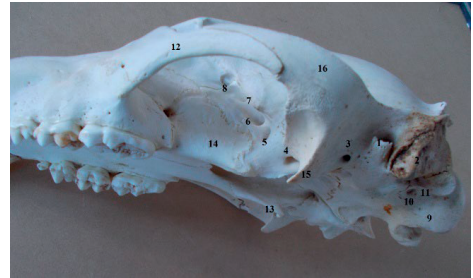


Figure 5. Lateral-ventral face of the skull in Eurasian brown bear (*Ursus arctos arctos*) - 1. External auditory canal; 2. The mastoid process of the temporal piramide; 3. Retro-auricular foramen; 4. Posterior alar foramen; 5. Anterior foramen; 6. Optic foramen; 7. Orbital fissure; 8. Ethmoidal foramen; 9. Occipital condyle; 10. Hypoglossal nerve foramen; 11. Paracondylar processes; 12. Zygomatic bone; 13. Pterygoid hamulus 14. Palatine bone; 15. The retroglenoid process; 16. The zygomatic process of the temporal bone

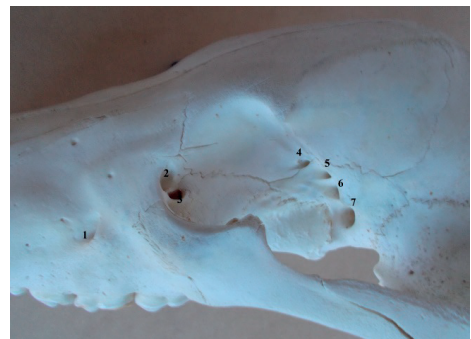

Figure 6. The lateral face of the skull in the Eurasian brown bear (*Ursus arctos arctos*) - 1. The infraorbital foramen; 2. The lacrimal foramen; 3. Vascular foramen; 4. Ethmoidal foramen; 5. Optic foramen; 6. Orbital fissure; 7 Foramen rotundum

The diastema or intervalveolar margin is occupied almost entirely by the canine alveolus.

At the level of the maxilla, the premolar and molar alveolar reliefs can be noticed, especially at the level of the carnassial tooth.

The ventral surface of the skull of the brown bear (*Ursus arctos*) presents at the caudal extremity, the convex condyles of the occipital, delimiting a wide and oval-looking foramen magnum. The paracondylar processes are obvious, with the free extremity drawn ventro-caudal, delimiting with the condyles of the occipital a narrow and deep ventral condylar

fossa. The foramen of the hypoglossal nerve is located at the level of the condylar fossa.

The basioccipital is wide, and on the sides, there are two small, ventrally-oriented processes, at the base of which a small fossa is observed.

The tympanic bulla is reduced, flattened dorso-ventral, and the muscular process is barely outlined.

The carotid foramen is located in the rostro-ventral plane, behind the tympanic bulla, and the jugular foramen is situated in a ventro-caudal direction, separated by a small bony blade.

Between the tympanic bulla, the paracondylar processes and the mastoid process, is situated an elongated and relatively deep fossa in ventro-latero-caudal position, in which are located the stylomastoid foramen and the articular surface for the tympanohyoid. The foramen lacerum is not present.

In the oral extremity of the tympanic bulla, at the border between it and the basisphenoid wing, the musculo-tubal duct is located laterally, and medially there are two superimposed foramina, separated by a thin bone blade, the one on the upper floor being represented by the foramen spinosum, and the one on the lower floor of a foramina, probably vascular (Figure 7).

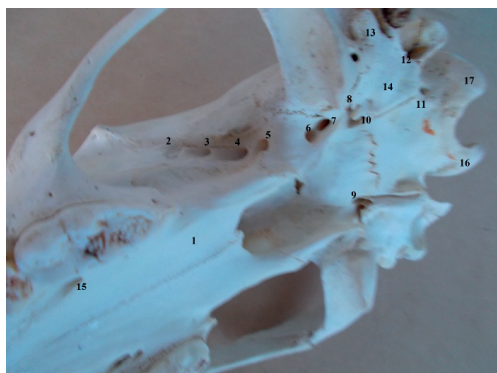


Figure 7. The ventral face of the skull in Eurasian brown bear (*Ursus arctos arctos*) - 1. Horizontal processes of the palatine; 2. The ethmoidal foramen; 3. Optic foramen; 4. Orbital fissure; 5. Foramen rotundum; 6. Caudal alar foramen; 7. Foramen ovale; 8. Musculo-tubal canal; 9. Spinous foramen; 10. Vascular foramen; 11. Jugular foramen; 12. Stilo-mastoid foramen; 13. External additive canal; 14. Tympanic bulla; 15. Major palatine foramen; 16. Paracondylar process; 17. Occipital condyle

The bodies of the basisphenoid and the presphenoid are broad, and the pterygoid bone has a highly underlined and ventro-caudal oriented hamulus. The pterygopalatine crests are long and oriented laterally into their caudal extremity. They delimit a wide guttural opening.

The articular surface for the mandible is arranged on the ventral side of the zygomatic process of the temporal bone, being represented only by a transversely elongated glenoid cavity, behind which is arranged a well-grown retroglenoid process and rostral curvature. At the level of the caudal surface of the retroglenoid process, a retroauricular foramen is observed in a dorso-caudal position.

The palatine arch, made by the palatine processes of the incisive bone, the palatine processes of the maxilla and the horizontal processes of the palatine, narrows in the caudal extremity.

The horizontal processes of the palatine are much elongated in the rostral extremity, ending sharply, having a relatively triangular appearance.

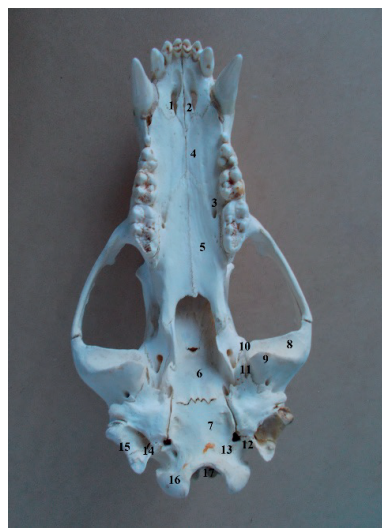

Figure 8. The ventral face of the skull in Eurasian brown bear (*Ursus arctos arctos*) - 1. Palatine fissure; 2. The interincisive canal; 3. Major palatine foramen; 4. The palatine process of the incisive bone; 5. Horizontal processes of the palatine; 6. Basisphenoid; 7. Bazioccipital; 8. Glenoid cavity; 9. The retroglenoid process; 10. Caudal alar foramen; 11. Foramen ovale; 12. Jugular foramen; 13. Foramen of the hypoglossal nerve; 14. The paracondylar process; 15. The mastoid process of the petrous part of the temporal bone; 16. Occipital condyle; 17. Foramen magnum



At the border between the rostral extremity of the palatine bone and the caudal extremity of the palatine process of the maxilla, near the dental alveoli, the major palatine foramina are arranged on the lateral parts. They extend rostrally with a small palatine grooves, reaching the level of the palatine fissures. Behind the major palatine foramina, we can observe a small accessory palatine foramen. The palatine fissures are wide in the rostral extremity, ending sharply in the caudal part and being arranged near the canine alveoli (Figure 8).

In the caudal third of the interincisive fissure, there is a small interincisive canal.

The nuchal face of the Eurasian brown bear (*Ursus arctos arctos*) has a relatively quadrilateral appearance.

In the dorsal plane, at the level of the nuchal face, a reduced external occipital protuberance is observed, from which the well nuanced nuchal crests descend on the lateral parts. The external occipital crest is well developed in the upper part, being reduced in size near the foramen magnum. On either side of the external occipital crest, below the nuchal ridges, there is a thickened tubercle for muscle insertion (Figure 9).

The paracondylar processes are short and do not exceed the occipital condyles in the ventral direction.

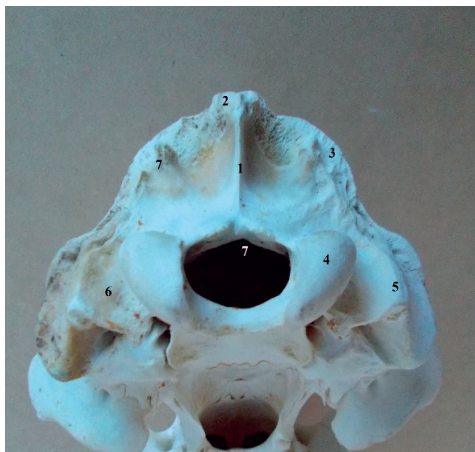

Figure 9. Ventral face of the skull in Eurasian brown bear (*Ursus arctos arctos*) - 1. External occipital crest; 2. External occipital protuberance; 3. Nuchal crest; 4. Occipital condyle; 5. Paracondylar process; 6. The condylar fossa; 7. Foramen magnum; 7'. Tubercle for muscular insertion

The mandible of the Eurasian brown bear (*Ursus arctos arctos*) is formed by a paired bone. The mandibles are articulated in the rostral part by synchondrosis.

The body of the mandible is short. The diastema is evident, presenting the canine alveolus (Figure 10).

The horizontal branch of the mandible has a relatively convex ventral edge, ending in a noticeable angular process, curved dorsally and flattened dorso-ventral, and slightly excavated on the dorsal part

On the lateral surface of the horizontal branch of the mandible, there is a mental foramen, accompanied by 2-3 accessory mental foramina (Figure 11).

At the level of the curved branch of the mandible, on the lateral side, a deep and relatively triangular-looking masseteric fossa can be seen. On the medial surface, the pterygoid fossa is superficial, and the mandibular foramen is placed near the caudal margin.

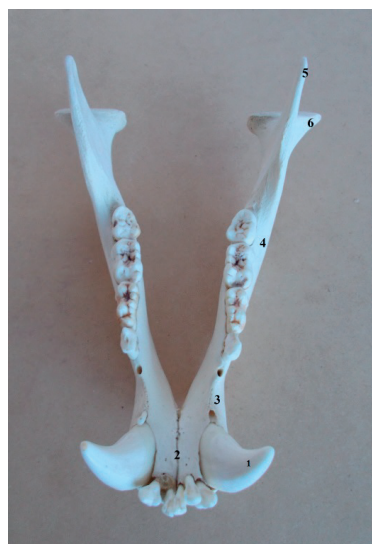

Figure 10. Eurasian brown bear mandible (*Ursus arctos arctos*) - dorsal view (original photo) - 1. Canine; 2. The body of the mandible; 3. Interdental space (diastema); 4. The horizontal branch of the mandible; 5. Coronoid process; 6. Condylar process

The coronoid process is strongly developed, with a rounded free end and slightly caudally oriented. The condylar process is short and has a convex surface. The corono-condylar notch is elongated and not very deep.

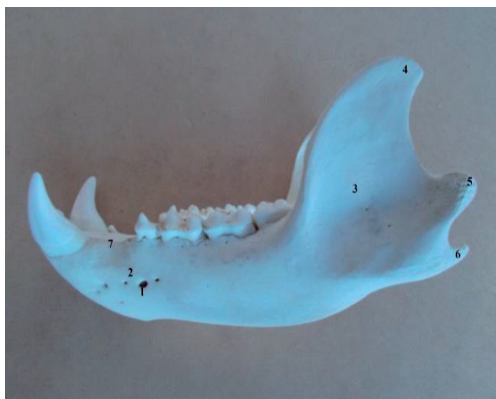

Figure 11. Eurasian brown bear mandible (*Ursus arctos arctos*) - side view (original photo) - 1. Mental foramen; 2. Accessory mental foramen; 3. Masseter fossa; 4. Coronoid process; 5. Condylar process; 6. Angular process; 7. Interdental space (diastema)

## CONCLUSIONS

The skull of the brown bear has an elongated and relatively narrow dorsal face.

The external sagittal crest is short, not very prominent, and the zygomatic processes of the frontal bone are very reduced.

The nasal bones do not articulate with maxilla.

The orbit is incomplete, there is an orifice between the maxillary and the lacrimal foramen, we assume it is of vascular nature.

The *foramen rotundum* and the rostral alar foramen are separated by an osseous blade.

The external auditory canal, circular in section, is strongly highlighted.

The tympanic bulla is reduced and flattened dorso-ventral, the muscular process is barely represented, and there is no *foramen lacerum*.

Between the tympanic bulla and the wing of the basisphenoid, there are two medial overlaid

foramina, a spinous foramen being dorsal, and a ventral vascular foramen.

The coronoid process of the mandible is well-developed, with the free extremity rounded and slightly drawn caudally, and the condylar process is short, with a convex surface.

The angular process of the mandible is curved dorsally, flattened dorso-ventral and lightly excavated on the dorsal face area.

## REFERENCES

- Atalar, O., Ustundag, Y., Yaman, M., & Ozdemir, D. (2009). Comparative anatomy of the neurocranium in some wild carnivore. *J Anim Vet Adv.* 8: 1542-1544.
- Cotta V. & Bodea M. (1969). *Vânatul României*, Edit. Agrosilvică, București.
- Getty, R. (1975). *The anatomy of the domestic animals*, Saunders Company, Philadelphia, London, Toronto, fifth edition.
- Jackson, T. (2011). *The world encyclopedia of animals*. Annes Publishing Ltd., Hermes House, London.
- König, H.E., & Liebich, H.G. (2004). *Veterinary Anatomy of Domestic Mammals*. Schattauer GmbH, Stuttgart, New York.
- Mihaylov, R., Dimitrov, R., Raichev, E., Kostov, D., Stamatova-Yiovcheva, K., Zlatanova, D., & Bivolarski, B. (2013). Morphometrical Features Of the head Skeleton in Brown Bear (*Ursus arctos*) in Bulgaria. *Bulgarian J Agric Sci.* 19: 331-337.
- Movahhedi, N., Kemi, H., & Shajiei, H. (2014). The study of skull of mammal carnivorous in Golestan state of Iran. *Iran J Anim Biol.* 6: 81-89.
- Șelaru N. & Goicea N. (2005). Situația și Managementul ursului brun în România, *Rev. Vânătorul și Pescarul Român*, nr. 2.
- Yousefi, M.H. (2016). Anatomical study of the Iranian brown bear's skull (*Ursus arctos*): A case report, *Iranian Journal of Veterinary Medicine*, 10(3):237-244
- \*\*\*-NominaAnatomicaVeterinaria (2017). Fifth edition, Published by the Editorial Committee Hannover (Germany), Ghent (Belgium), Columbia, MO (U.S.A.), Rio de Janeiro (Brazil).



# CLINICAL SCIENCES



