

THERAPEUTIC APPROACH IN VETERINARIAN ONCOLOGICAL EMERGENCIES

Dan CRÎNGANU¹, Raluca NEGREANU¹, Ionuț GÂRJOABĂ¹, Iuliana CRÎNGANU²

¹University of Agronomic Sciences and Veterinary Medicine of Bucharest,
Faculty of Veterinary Medicine, 105 Splaiul Independenței, Bucharest, 050097, Romania,
contact: 0040213180469

²University of Agronomic Sciences and Veterinary Medicine of Bucharest, Faculty of
Engineering and Management of Animal Production - Department of Growth and Processing
Technologies, 59 Mărăști Blvd, Bucharest 011464, Romania, contact: 0040213182266

Corresponding author email: ralucacringanu@yahoo.com

Abstract

Oncological emergencies can occur at any time during an neoplastic pathology or during specialized treatment, and must be identified and properly addressed as early as possible, so as to determine a maximum favorable response. Emergencies in cancer can be represented by iatropathic disease (Cringanu, 2013), paraneoplastic syndromes or the cancer itself. The earlier we diagnose, the better we can establish a treatment with a successful result. This article aims to present treatment protocols in the most common cases of veterinary oncological emergencies. The main objective of our research was to establish a unitary conduct for a fast and correct diagnosis and an efficient treatment of oncological emergencies, before their effects became irreversible.

Key words: oncology emergency, paraneoplastic, chemotherapy, disease.

INTRODUCTION

The emergency events in oncology can be defined as acute pathological conditions determined by the clinical evolution of paraneoplastic syndromes, a consequence of the chemotherapy disease or the evolution of the neoplastic disease.

Assessing the diagnosis and performing specific therapy should be rapid and address the syndromes in order of their severity (Cervantes & Chirivella, 2004). The diagnosis of the oncology patient's emergency must be determined in order of priority and type of emergency.

The choice of therapeutic strategy and the combination of techniques and methods is made personalized according to the clinical condition of the patient at the time of diagnosis by anamnesis, general physical examination evaluation, TNM clinical staging, monitoring of vital functions, histopathological type and appreciation of the response to the therapies already performed (Cringanu & Crivineanu, 2009)

Oncological emergencies order of frequency from most to least frequent, are:

- Paraneoplastic metabolic syndromes: hypoglycemia, cachexia, hyponatremia, hypercalcemia, hypoalbuminemia, hyperkaleaemia and hypocalcemia (Krug & Michl, 2018).
 - Hematologic syndromes: lymphocytosis, neutrophilia, anemia, thrombocytopenia (Cringanu, 2013).
 - Cancer related: TLS¹, thoracic hemorrhagic effusions, peritoneal effusions, pathological fractures from bone neoplasia (Ehrhart et al., 2013), etc.
 - Obstructive or structural emergencies, due to space-replacing tumors: pain (Nolen, 2004).
 - Iatrogenic emergencies include: chemotherapy induced toxicity, local subcutaneous extravasation or anaphylactic reactions. (Shmuel & Cortes, 2013).
- Less than 25% of animals have adverse effects to chemotherapy (Chun et al., 2001).

¹ Tumor lysis syndrome

Although not all of these emergencies are documented in this paper, it is important that we check for early signs, because oncology emergency may also be aggravated by pre-existing liver disease, kidney disease, hematologic disease, neurological disease, disease evolution or therapy associated toxicity and if we recognize the possibility of an emergency we can prevent it.

A clear goal is to establish the diagnosis and specific therapy based on standardized protocols, to be used by all clinicians. Another major objective of this paper is the description and screening of toxic effects of chemotherapy previously administered to some of the cancer patients, and how to prevent the iatrogenic syndromes that occur when treatment is combined with metabolic paraneoplastic syndromes.

The 14 cases studied have been selected for the variety of symptoms and their evolution has been documented for teaching purposes. The goal of the oncological therapy is to control the pain, to restore metabolic balance, to alleviate the paraneoplastic symptoms and eventually restore the morpho-structural integrity of affected tissues.

MATERIALS AND METHODS

We used the medical observations resulted from first time examination and follow-ups of specific oncologic cases over a period of 12 months, on 14 dogs of different breeds, genders, weight and ages with malignant tumors in advanced clinical stages, III and IV. Five of the cases that presented with oncological emergencies benefited from chemotherapy, previously administered at different clinics. The 14 cases are divided into 3 lots, depending on the oncological emergency determined by a certain type of cancer.

Lot no.1 is comprised of 2 cases of Non-Hodgkin malignant lymphoma exhibiting compressive or obstructive syndromes and 3 cases with inflammatory carcinoma (mastitis carcinomatos²) exhibiting lymphedema and

stasis edema. Also, we included one case of osteosarcoma with pain syndrome due to a pathologic fracture.

The second lot is comprised of cases that display metabolic syndromes such as histamine discharge, liver and kidney failure in 3 cases of cutaneous mastocytoma and one case of osteosarcoma that was included as an example of severe hypercalcemia due to tumor and bone lysis.

The 3rd lot includes patients that suffer from iatrogenic diseases and different types of chemotherapy toxicity (renal, hepatic). We selected 4 cases, 2 mammary gland adenocarcinomas and 2 lymphoma cases, that exhibited important symptoms.

The examined patients were part of case studies of the Internal Medicine Department and Oncology Department. We gathered complete hematology and biochemical panels for each of the patients. Result from adenograms, fine-needle aspiration biopsies from both cancer tissue and healthy tissue were collected and biopsies by excision were also attached to the patient files. Samples have been stained by May-Grunwald-Giemsa or Trichromic Masson methods. The imaging departments provided us with ultrasounds, X-rays, CT scan results completing the diagnosis protocol in order to identify soft tissue and bone modifications in each case, as needed.

In these emergencies, the investigations used were chosen strictly in the context of each case to establish the optimal therapy and only relevant images have been included in the article.

The cytopathology and/or histopathology diagnosis was already established for the cases, upon arrival at the Oncology Clinic. The present paper highlights the treatment of the oncological emergency for each case.

Out of the 14 patients, 2 have died (one lymphoma and one mastocytoma patient), necropsies were performed and histopathology samples from both dogs were taken (lymph node samples, liver and kidney samples). The most representative images are illustrated in this paper.

² MC

The treatment protocol for each emergency was established taking into consideration acute/life-threatening symptoms and TNM of each patient.

The canine patient's clinical record also include basic data: weight, age, medical history and co-morbidities in order to establish an exact protocol for the chemotherapy and an oncological emergencies protocol.

Table 1. Drugs used in the treatments in this article

Drug	Recommended dose
Dexamethasone	0.2-0.5 mg/kg, up to twice a day
Hydrocortisone Hemisuccinat	10-15 mg/kg, i.v. ³ , shock dose
Prednisolone 5 mg	0.5-1.0 mg/kg
Tramadol 50 mg/ml	3.0-4.0 mg/kg i.m., every 8 to 12 h
Sedam 35 mg/ml	1.0-3.0 mg/kg, p.o., as needed
Ketamine	0.2-0.3 ml/kg i.m. ⁴
Metamizol	25-35 mg/kg, as needed
Piroxicam	0.3 mg/kg, p.o. ⁵ , every other day
Meloxicam 5mg/mL	0.2 mg/kg, s.c.
Meloxicam ointment	as needed
Mibazon ointment	as needed
Cefort	50 mg/kg/zi i.v.
Cefa-cure 50 mg	20 mg/kg, p.o., every 24h
Granisetron	0.6 mg/kg, s.c., i.v.
Emeset	0.5-1.0 mg/kg, i.v., every 12-24 h
Ondansetron	0.5-1.0 mg/kg, i.v., every 12-24 h
Osetron	0.5-1.0 mg/kg, i.v., every 12-24 h
Ranitidine	1.0-2.0 mg/kg, p.o., every 12 h
Zantac	1.0-2.0 mg/kg, p.o., every 12 h
Arnetin	1.0-2.0 mg/kg, p.o., every 12 h
Cimetidine	5.0-10.0 mg/kg, p.o. every 6-8 h.
Leukeran	2 mg/10 kg, p.o. once a week
Holoxan	200 mg/m2, i.v. every 14 days
Carboplatine	50 mg/m2, i.v. every 21 days
Cyclophosphamide	50 mg/day, p.o. every 14 days
Furosemide 20 mg/ 2 ml	10-20 mg, i.v.
Mannitol 20%	200 mg/kg, i.v.

³ intravenous administration

⁴ intramuscular administration

⁵ oral administration

Drug	Recommended dose
Aspatofort	10 ml i.v., 2 times a day in Glucose solution
Etamsylate	10-15 mg/kg, every 6 h, i.v.
Vitamin K	2.2 mg/kg s.c.
Adrenostazin 1.5 mg/5 ml	1.5-2.0 mg/20 kg. s.c.
No-Spa 40 mg/2 ml	40 mg., s.c. ⁶ every 24 hours
Metoclopramide syrup	0.2-0.5 mg/kg., every 6-8 h
Enteroguard	1 tb/3 kg, p.o. for 7 days
Entero-Chronic	4 g/day/30 days p.o.
NaCl 0.9 g/100 ml, Glucose 5%, Ringer Lactate, Aminoplasmal Solution	as need/body mass/ parameters i.v.

RESULTS AND DISCUSSIONS

Lot 1 - Compressive/obstructive syndromes and pain syndrome in 2 non-Hodkin's Lymphoma (NHL) patients (*Patient A*, common breed, 12 years, M;

Patient B, Corsican Dog, 8 years old, F) an osteosarcoma patient (*Patient C*, Setter, 11 years, F) and 3 inflammatory carcinoma MC patients (*Patient D*, Bichon Frise, 9 years, F; *Patient E*, common breed, 11 years, F; *Patient F*, French Bulldog, 8 years old, F).

Image procedures used in our diagnosis are: x-ray for patient C with osteosarcoma (Figure 5) and CT scans for patients A and B.

The cranial vena cava syndrome (CVCS) occurs once the tumor compresses the vein in its path. Venous obstruction may be due to compression, invasion, deep vein thrombosis or vein fibrosis. In the 2 NHL patients it was secondary to the malignancy. As a result of the cancer invasion/compression, an increase in central venous pressure occurs determining edema and collateral circulation (Figure 1).

Diagnosis is clinically established relatively easily, in the initial stages of CVCS and can be confused with heart failure (a feature of differentiation being the absence of jugular pulses and absence of tachycardia).

Symptoms suggestive of CVCS consist of progressive edema of the neck, followed by

⁶ subcutaneous administration

facial and forelimb edema, dyspnea associated with tracheal compression, head, neck and chest edema, superficial venous ectasis over the chest.

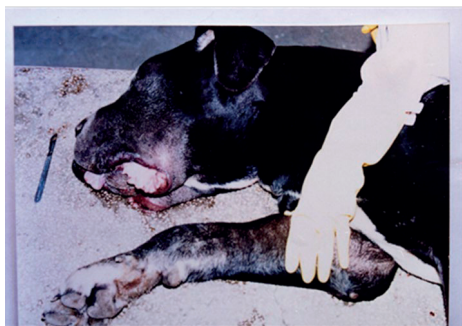

Figure 1. Severe edema of the head (Patient A)

The treatment is symptomatic with oxygen therapy for dyspnea, Furosemide to reduce edema and Dexamethasone or Hydrocortisone in high doses, according to the prospectus, in order to reduce inflammation. The prime cause established to be neoplastic in origin, is treated with chemotherapy. Leukeran 2 mg/10 kg once a week, or Holoxan 200 mg/m² once every 14 days recommend after the acute episode. Unfortunately Patient A died. During the necropsy, we collected lymph nodes that presented specific NHL lymphadenopathy (Figure 2).

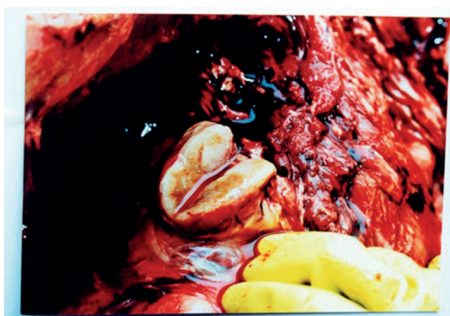

Figure 2. Necropsy lymphadenopathy (Patient A)

Obstructive syndromes due to the thromboembolic disease (TED), also known as venous thromboembolism (VTE), includes a broad spectrum of manifestations, from the most common - acute venous

thrombosis (AVT)- to the most severe - deep venous thrombosis (DVT) and pulmonary embolism (PE). In this study, we encountered AVT in all of the 3 cases of inflammatory carcinoma (MC⁷) (Figure 3).

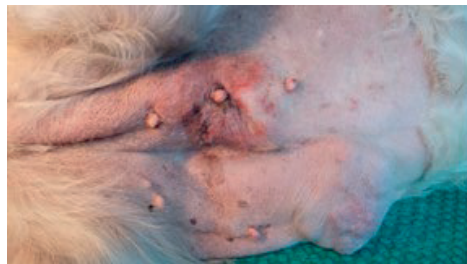

Figure 3. Thromboembolic disease (AVT) in MC (Patient D)

The increased risk of thrombosis is due to tumor release of a procoagulant TF⁸ responsible for triggering the extrinsic coagulation cascade.

For the treatment of this type of inflammatory carcinoma, we used for the symptomatic treatment of the emergency: locally: Mibazon ointment alternating with Meloxicam ointment, intravenous: Cefort and Mannitol, subcutaneous: Furosemide at 24 hours, intramuscular: Tramadol at 12 hours. This is a palliative solution that relieves paraneoplastic syndromes. It is recommended to start oncological treatment with intravenous Carboplatine at 21 days for a long term result.

The pain syndrome is a specific and frequent syndrome in cancer patients. The definition proposed by the International Association for the Study of Pain considers pain to be an unpleasant sensory and emotional experience, associated with actual or potential tissue destruction, or described in terms of such destruction. A quick and reliable method we use to clinically assess the dogs in acute pain (emergency evaluation) in this lot, is the short form of the Glasgow Composite Measure Pain Scale

⁷ mastitis carcinomatosa

⁸ tissue factor

(GCMPS). Analgesic intervention was made at a 6/24 (or 5/20) level (Figure 4).

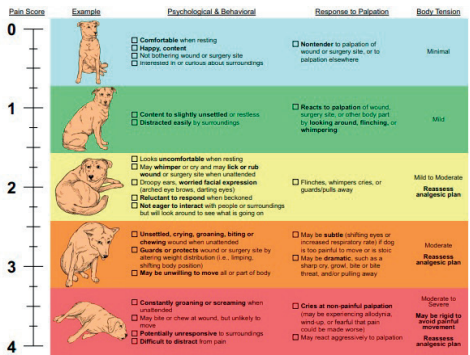


Figure 4. Veterinary Anesthesia & Analgesia Support Group www.vasg.org/pdfs/ CSU_Acute_Pain_Scale_Canine.pdf

In our cases, the pain syndrome presented as an emergency for the patient with osteosarcoma and two of the dogs with MC. All of the 14 patients experienced some form of pain, but only these three were considered an emergency because of the high level of pain on the GCMPS and acute presentation (spontaneous fracture - Figure 5 - due to the osteolytic process in the radius with osteosarcoma and intense inflammatory reaction overlapping severe infection in the patients with MC).

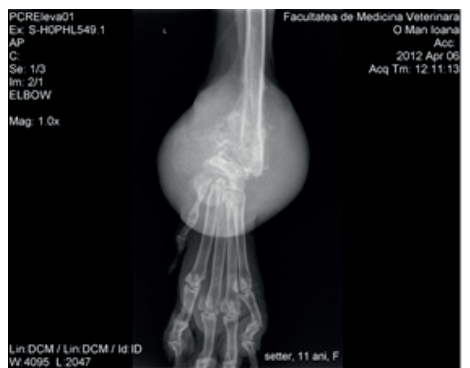

Figure 5. Spontaneous fracture due to the osteolytic process in a radius with osteosarcoma (Patient C)

Pharmacological agents used were non-steroidal anti-inflammatory drugs, opioid substitutes and pyrazolones (Table 1). In

addition to analgesics, substances with sedative or tranquilizing properties (a combination of Ketamine and Sedan) can be administered to reduce anxiety, pain and improve the effectiveness of analgesics (opioid substitutes: Tramadol and nonsteroidal anti-inflammatory drugs: Piroxicam and Meloxicam).

Lot 2 - Metabolic syndromes or paraneoplastic syndromes are clinical or morphological manifestations defined as "distant effects" produced by the tumor-induced release of peptide hormones that initiate an immune reaction. This leads to clinical and lab parameter modifications, without a dependency to the primary tumor's size or spread (Krug & Michl, 2018). These syndromes occur in addition to the local, systemic or non-metastatic manifestations that may occur. It is expressed in the form of a complex functional and pathological manifestations associated with the tumor-specific symptoms, with an initial insidious evolution but with increasing gravity as the tumoral cells disseminate in the body. The following were the most common syndromes accompanying the cancer disease of our 3 patients with MCT⁹ (*Patient G*, Shar-Pei, 8 years, F; *Patient H*, Shar-Pei, 11 years, M; *Patient I*, Boxer, 7 years, M) and one patient with osteosarcoma (*Patient J*, Great Dane, 7 years, M).

Patient H and patient I presented with cachexia. This is a specific metabolic imbalance, characterized by severe decrease of body weight, through loss of muscle mass. Cancer induced alterations in host energy metabolism or cachexia are probably the most common paraneoplastic syndromes in human and veterinary medicine.

Hypocalcemia caused clinically significant symptoms in our two patients: muscle spasms and convulsions.

Hipoalbuminemia is the primary plasma change caused by the "hunger" of malignant tumor cells.

⁹ mast cell tumors

Hypoglycemia is a frequent metabolic manifestation in oncology by the exaggerated consumption of carbohydrates by tumor cells.

Hypercalcemia defined as elevated calcium levels over normal limits is the most common metabolic disorder associated with bone metastases and/or bone lysis and was a problem in patient J.

Hyperkalaemia is the major potentially fatal electrolyte disorder defined as a potassium increase of more than 5.0 mEq/l, due to the release of cellular debris through cell destruction. The most severe manifestation in our patients G and I has been ventricular arrhythmia.

Hyponatremia by volumetric overload is caused by the accumulation of fluids in the extracellular compartment by reducing the circulating volume

The treatment of this type of metabolic abnormalities is symptomatic and includes Aminoplasmal and Ringer's lactate rehydration solutions to compensate for electrolytes and metabolic acidosis.

Table 2. Paraneoplastic syndromes and patient parameters

Paraneoplastic syndrome	Case	Value	Normal Range
Hypocalcemia	Patients H, I	> 9 mg/dL	9-12 mg/dL
Hypoalbuminemia	Patient G, I	> 2.0-2.5 g/dL	3.5-5 g/dL
Hypoglycemia	Patients G, H, I	60-65 mg/dL	75-125 mg/dL
Hypercalcemia	Patient J	18.8 mg/dL	9-12 mg/dL
Hyperkaemia	Patients G, H, I	< 5 mEq/l	3.5-5 mEq/l
Hyponatremia	Patient G	< 120 mEq/l	136-145 mEq/l

The clinical signs of mastocytoma may be complicated by signs attributed to the release of histamine, heparin, and other vasoactive amines. Occasionally, mechanical manipulation during examination may lead to degranulation and erythema in the areas adjacent to the formation. This phenomenon was given a name: Darier's sign (Figure 6). Healing after surgical excision is also

difficult due to the enzyme gelatinase secreted by malignant mast cells. This is also the reason for the appearance of specific edema. When mast cell degranulation occurs ulcers form in the stomach or intestines, in different stages of evolution and cause vomiting and loss of appetite (patients G and I), lethargy and melena (patient H).

H2 receptor antagonists counteract the effects of degranulation and prevent the aggravation of the disease (Table 3). Less commonly, these chemicals and compounds can cause anaphylaxis (Pinard, 2020). Although none of our patients exhibited this type of emergency, we recommend antihistaminic treatment preventively (Table 3).

The treatment must also include antibiotics (Cefort) and anti hemorrhagic therapy (Etamsylate and vitamin K)

Table 3. Selected treatment for MCT patients

Drug action	Product	Case
Corticosteroids	Hydrocortisone	Patients G, H, I
	Dexamethasone	
	Prednison	
H2 receptor antagonists	Ranitidine	Patients G, H, I
	Zantac	
	Arnetin	
	Cimetidine	

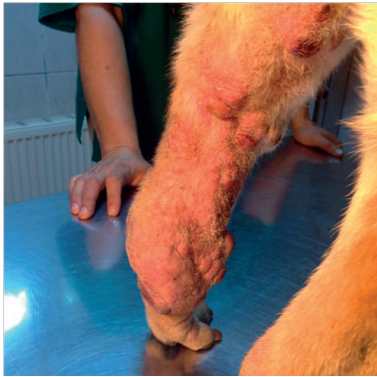

Figure 6. Severe edema and infiltrative cutaneous mastocytosis. Darier's sign (Patient G)

Lot 3 - The iatrogenic disease is the complete palette of pathological syndromes induced by chemotherapy toxicity, the whole variety of symptoms that occur following the non-selective action on the entire

organism due to the chemotherapy overlapping the neoplastic disease and paraneoplastic syndromes. Four of the 14 patients have exhibited at least one of these symptoms as emergencies.

The emergencies we encountered in the 4 cases included in this lot, 2 mammary gland adenocarcinomas (*Patient K*, common breed, 13 years, F; *Patient L*, Maltese, 12 years, F) and 2 lymphoma cases (*Patient M*, Boxer, 8 years, M; *Patient N*, Dalmatian, 6 years, M)

Emesis is the reflux of gastric contents caused by digestive tract damage.

In our cases, the emesis was precocious - determined by the administration of an oral chemotherapy drug with digestive absorption (Cyclophosphamide) for patient M and N and ultra precocious - based on the Pavlovian reflex created by an experience before chemotherapy for patient K and L.

Table 4. Selected treatment for iatrogenic emesis

Symptome	Drug action	Product	Case
Emesis	5-HT ₃ antagonist antiemetic	Granisetron	Patients M, K
		Emeset	
		Ondansetron	
		Osetron	
		Zophren	
	H2 receptor antagonists	Ranitidine	Patients K, M, N
		Zantac	
		Arnetin	
		Cimetidine	

Enteric syndrome - Diarrhea occurs as a consequence of the local irritation by some chemotherapy agents or oral treatments at high doses and for prolonged periods, which accentuates peristalsis, information obtained through ultrasound examination (patient M) and has been treated symptomatic with No-Spa 40 mg/2 ml s.c. (40 mg every 24 hours), Entero-Chronic (4 g/day/30 days) and Enteroguard M (1 tb/3 kg, for 7 days) for patient M

Chemotherapy immunosuppression is a syndrome that initially affects cell mediated

and then humoral mediated immunity, due to mechanisms such as: inhibition of stem cell proliferation, destruction of circulating or fixed immunocompetent cells, decreased circulating antibody concentration.

Thrombocytopenia in patient L, a value of 60 thousand/microL (normal value 117-460 thousand/microL) was determined by megakaryocyte cytolysis at the central medial level by the metabolic inhibitor effect. Clinically, it was manifested by a purpura syndrome following administration of the chemotherapy agent Cyclophosphamid. We decided to give the pacient a blood transfusion and recommend a long term treatment with immunomodulatory drugs after the patient overcomes the acute episode.

Acute interstitial nephritis and hemorhagic cystitis diagnosed in patient M are caused by the excretion of the chemotherapy he had received with Cyclophosfamide at renal level. The toxic effect of the chemotherapy determined an acute reaction in the kidneys and severe irritation of the mucosa in the urinary bladder, visible in the ultrasound. The selected therapy was a cocktail of Etamsilate every 4h and Adrenostazin to stop the bleeding, vitamine K p.o., and Manitol i.v. for 3 days after the patient overcomes the acute episode.

Induced jaundice syndrome is the excess accumulation of conjugated bilirubin in the tissues or blood stream. Clinically, jaundice has been noted in pigmented skin, mucous membranes and sclerotic of patient M and we classified it as: hepatic - caused by large and repeated administration of Cyclophosphamide as an agent of alkylation (Table 5). This type of symptoms are determined by the oxidative degradation that causes the occurrence of toxic liver metabolites in the form of acrolein and chloroacetaldehyde. The emergency choleretic therapy used Metoclopramid syrup p.o every 4 h, No-Spa s.c. every 8 h foar 24 h and Colebil p.o. for 3 days.

Table 5. Blood parameters for patient M

	UM	Results	Normal value
GPT/ALT	U/L 37°C	385	5-60
GOT/ASAT	U/L 37°C	72.4	>35
GGT	U/L 37°C	12.4	>9
Bilirubin	mg/dL	2.12	>0.90
Urea	mg/dL	68	>50
Creatinine	mg/dL	2.9	>1.80
Alkaline phosphatase	U/L 37°C	386	>200
Acid phosphatase	U/L 37°C	132	<125
Prostatic phosphatase	U/L 37°C	189	Sub 190

Unfortunately patient M (Boxer, 8 years, M) has died during the case study. Kidney and liver samples were taken in order to confirm organ reaction to the chemotherapy (Figures 7 and 8).

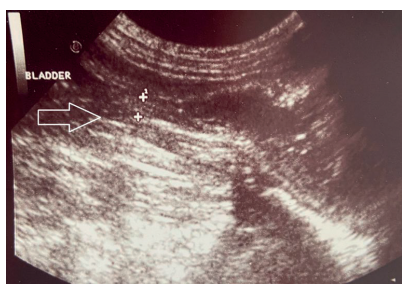


Figure 7. Bladder with visibly thickened wall due to the action of the chemotherapy (Patient M)

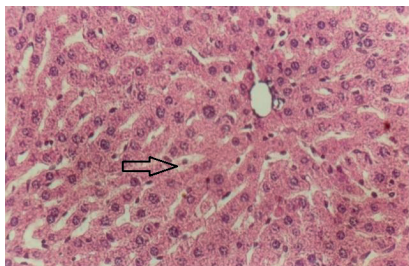


Figure 8. Liver cell necrobiosis, with caryolysis and cytolysis caused by Cyclophosphamide. Necropsy sample from patient M

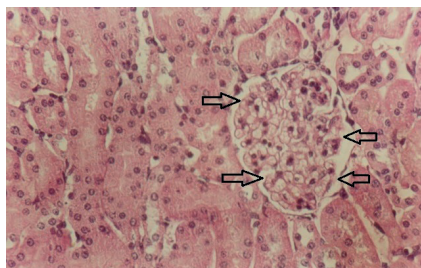


Figure 9. Glomerular edema after Cyclophosphamide therapy. Necropsy sample from patient M

CONCLUSIONS

Emergency oncology has the same principles as any other kind of medical emergency. Triage is of up-most importance. It saves time and it saves lives.

In order to have a correct and fast triage, we recommend a complete medical chart of the patient, after the initial threat is treated (hemorrhage stopped, edema treated, pain alleviated, etc.). The more we know, the better we can treat.

Speed. The information must be gathered fast and must be selected regarding the prime emergency (example: an x-ray for severe pain to confirm a fracture, in a patient with osteosarcoma, after pain management therapy has begun)

Paraneoplastic syndromes are frequent and aggressive, but respond well to re-balancing therapy.

A printed Glasgow Composite Measure Pain Scale (GCMPs) is of great help in emergency situations. Also printed protocols and doses for the emergencies presented in this article are very useful. The combination of sedatives and tranquilizing drugs will improve the effectiveness of analgesics. Also edema and mastocytoma erythema respond well to high shock doses of Hydrocortisone combined with Dexamethasone

The majority of oncology emergencies have reversible effects if caught in time.

Once the emergency has passed, the correct chemotherapy and regular follow-ups will help keep things under control.

ACKNOWLEDGEMENTS

The authors would like to thank the Internal Medicine Department and the Department of Pathology at the Faculty of Veterinary Medicine, Bucharest, Romania and thank you to our colleagues from 4Vet Radiology Veterinary Imaging Clinic for their assistance.

REFERENCES

- Baker, R., Lunmsden, L.M. (2010). *Color atlas of cytology of dog and cat*. St. Louis, U.S.A.: Mosby Publishing House.
- Banks, W.J. (2005). *Applied Veterinary Histology. Second Edition*. Baltimore, U.S.A.: Williams & Wilkins Publishing House
- Cervantes, A., Chirivella, I. (2004). *Oncological emergencies. Annals of Oncology* 15. 299–306.
- Crînganu, D. (2009). *Pet Pathology. General Oncology IInd Edition*. Bucharest, RO: Printech Publishing House.
- Crînganu, D., Crivineanu, M. (2009). *Veterinary Oncological Therapy*. Bucharest, RO: Printech Publishing House
- Crînganu, D., Codreanu, M., Negreanu, R., Negreanu, R.E. (2013). *Iatropatic disease induced by wrongly administered chemotherapy* (pp. 74-76). Bucharest, RO: Scientific Works. Series C. Veterinary Medicine 59(3).
- Delmann, H. D., Brown, E. M. (2005) *Textbook of Veterinary Histology, Third Edition*. Philadelphia, U.S.A.: Lea & Febiger Publishing House.
- Ehrhart, N.P., Ryan, S.D., Fan, T.M. (2013). *Tumors of the skeletal system* (pp. 463–503), Small Animal Clinical Oncology 5th Edition.
- Nolen, R.S. (2001). Silent suffering. *Journal of the American Veterinary Medical Association*. Dec 15; 219(12), 165.
- Nolen, R.S. (2004). The problem with pain. Veterinarians are making a thorny issue a priority. *Journal of the American Veterinary Medical Association*, Aug 1; 219(3), 288-289.
- Robert, E., Willner, M. (2006). *The Cancer Solution*, Canada. Peltec Publishing House.
- Pinard, C. (2020). *Mast Cell Tumors in Dogs*, vcahospitals.com.
- S Krug, S., Michl, P. (2018). Metabolic disorders as paraneoplastic syndromes. Berlin, *Jurnal: Der Internist*, Feb; 59(2), 114-124.
- Shmuel, D.L., Cortes, Y. (2013). Anaphylaxis in dogs and cats. *Journal of Veterinary Emergency and Critical Care*, 23, 377–394.
- Van Dijk, J.E., Gruys, E., Mouwen, J.M. (2007). *Color Atlas of Veterinary Pathology, Second Edition*, Spain, Saunders Elsevier Publishing House.
- White A.S.R. (2007). *Manual of small animal oncology*, London, U.K., British Small Animal Veterinary Associations Publishing House.