

## TRICHOGRAM - A HANDLE AND VALUABLE TOOL IN DERMATOLOGY PRACTICE

Carmen NEGOIȚĂ<sup>1</sup>, Valentina NEGOIȚĂ<sup>2</sup>

<sup>1</sup>USAMV of Bucharest - Faculty of Veterinary Medicine, 105 Independence Splai,  
District 5, Bucharest, Romania

<sup>2</sup>Institute of Oncology "Prof. dr. Alex. Trestioreanu", 252 Fundeni Road,  
District 2, Bucharest, Romania

Corresponding author email: carmennegoita2020@gmail.com

### Abstract

*In dermatology practice, hair-loss along with pruritus represents a very common and challenging problem. Persistent or transient hair-loss is associated to a lot of skin disorders, being of secondary origin in the most cases. The evaluation of alopecic patient for diagnostic assessment should include a complete history, a general and dermatological examination followed by suitable tests. Among them, trichogram is recognized as an easy and fast aid for investigation of troubles in hair anatomy and hair growth. The present study describes some distinct trichography aspects from alopecic dogs, cats and buffaloes which were examined at Dermatology Service of Veterinary Medicine Faculty from Bucharest. In summary, trichogram offers a definitive diagnostic especially for parasitic, fungal-associated and self-induced alopecia, but also an indicative data for many other skin and hair disorders.*

**Key words:** hairs, alopecia, microscopy.

### INTRODUCTION

Alopecia is partial or complete lack of hair in areas where it is normally present. It is basically classified into congenital and acquired alopecia, and etiologically divided into functional, structural and traumatic events. A hair-loss patient needs a systematic approach for identification of inflammatory or non-inflammatory origin of alopecia, starting with a complete history and identification of clinical pattern of lesions: solitary, multifocal or patchy hair-loss, symmetrical or diffuse alopecia; presence of papules, pustules, seborrhea; presence/absence of pruritus (Moriello & Mason, 1995). The clinically formulated differential diagnosis should be argued by several simple to complex tests, including trichogram, acetate tape preps, scraping, Wood's lamp exam, cytology and even biopsy.

The simplest and non-invasive way to investigate hair disorders consists in microscopic examination of plucked hairs from the periphery of alopecic areas (Medleau & Hnilica, 2006). This test can provide information about abnormalities of hair cycle (telogen/anagen ratio), acquired hair shaft defects (traumatic damage, hair casting, abnormal shapes), genetic hair shaft defects (pigmentary disorders) and

also the presence of parasitic or fungal elements. This paper aimed to reconfirm the real support of trichogram in routine veterinary dermatology practice.

### MATERIALS AND METHODS

Our study included 20 dogs, 10 cats and 10 buffaloes (hair samples), exhibiting persistent pruritus and hair loss with different distribution. In dog and cat patients, hairs were gently sampled from the periphery of alopecic lesions, in the direction of hair growth, using a hemostatic forceps. The plucked hairs were then placed on a glass slide containing a drop of mineral oil and covered by a coverslip and thereafter examined under a low power (x4, x10, x20). Trichography consisted in the microscopic examination of the whole hairs involving hair root (for anagen/telogen phase), hair shaft (for integrity of cuticle, cortex, medulla, and pigment distribution) and hair tip (for signs of damage).

### RESULTS AND DISCUSSIONS

The microscopic findings of hairs from examined dogs, cats and buffaloes were grouped according to the following criteria:

1. Traumatic damage of hair shaft, very suggestive for pruritic dermatitis, especially allergies (Figures 1, 2, 3).
2. Genetic and acquired unusual shapes of hair shaft (Figures 4, 5).
3. Loss of cuticle, cortex and/or medulla integrity (Figures 6, 9).
4. Diffuse cuticle defects (Figure 7).
5. Pigmentary abnormalities (Figure 8).
6. Hair casting (Figures 10, 11, 16).
7. Presence of different parasitic and fungal elements (Figures 9, 10 and 12 to 16).

In dogs, self-induced alopecia was seen with atopy and sarcoptic mange, and consisted in traumatic damage of hair shaft (broken hair tips, hair shaft fractures) due to chronically and severe pruritus (Figures 1, 2, 3). In cats, similar findings have been associated with flea allergic dermatitis (FAD) and eosinophilic syndrome.

We have also been found unusual shaped hairs, both in dog and cat with different pathology. Thus, in a kitten, twisted hairs indicated a congenital, structural hair abnormality known as *pili torti* (Figure 4) and in parallel, abnormal hair shapes with the loss of hair cuticle and cortex integrity were detected in a geriatric dog with hepatocutaneous syndrome caused by underlying metabolic disorders (Figures 5, 6, 7).

Furthermore, severe damage of hair's structure was noticed in fungal infections produced by *Microsporum* and *Trichophyton*, especially in long haired cats, with active infection. First step of fungal infection was proved by the adherence of the arthroconidia to corneocytes from cuticle hair followed by the germination with production of hyphae which penetrated the anagen hair shaft (endothrix invasion - Figure 9). Following hyphal invasion of the hair shaft, sleeves of infective spherical microspores were observed on the surface of the hairs (ectothrix invasion - Figure 10).

Hair pigmentary abnormalities could also be detected by trichoscopy, both in puppy and kitten, reflected by abnormal clumping of melanin granules in the hair shaft and root (Figure 8). Pigmentary disorders are generally associated with congenital alopecia and commonly encountered in dogs with color

dilution alopecia (CDA) and black hair follicular dysplasia (BHFD).

Trichogram was also very useful in the diagnosis of demodicosis in juvenile dogs, particularly for difficult areas (around the eyes, nail beds) and very painful lesions. Trichogram is considered to be 75-80% more sensitive than skin scrapings in demodicosis diagnosis. We recommend it for solitary alopecia and paronychia due to *Demodex* mites, which appear as adults, nymphs, larvae or eggs (Figures 12, 13). In dry form of demodicosis, but also in dermatophytosis with *Microsporum canis*, trichoscopy showed a lot of follicular casts or sheaths of sebum and keratin accumulation around hair shafts (Figure 11).

In hair samples from buffaloes occurring diffused alopecia, focal leukotrichia, severe seborrhea and pruritus, we identified a concomitant pediculosis with *Haematopinus trunculatus* and chorioptic mange (Figures 14, 15, 16). Louse infestation is not a commonly condition in dogs and cats, but more often in farm animals leading to skin irritation, anemia, anorexia, restlessness and reduced productivity (Butler, 1985; Veneziano et al., 2003).

In veterinary dermatology, a lot of hair loss conditions are recognized, either of primary or secondary origin, such as, genetic/congenital hair defects, endocrine/metabolic diseases, immunologic, parasitic and fungal hair disorders, psychogenic induced alopecia, drug-induced alopecia, traumatic or paraneoplastic alopecia (Colombo, 2010; Paterson, 2002). Acquired alopecia is usually of higher incidence compared to congenital alopecia (Geary, 1986).

In dermatology practice, post-inflammatory alopecia commonly found in dog and cat (Guaguère, 2008) is mainly caused by infectious folliculitis with *Staphylococcus*, *Demodex* mites and *Dermatophytes* fungi. Before trichogram, clinical pattern of alopecia may provide useful diagnosis clues. Thus, symmetrically generalized alopecia without inflammation implies the alteration in hair cycling (functional alopecia), but non-symmetrically localized alopecia with inflammation indicates the loss of the follicular structure (structural alopecia).

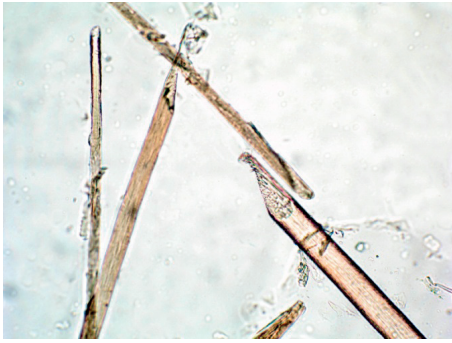


Figure 1. Dog hairs - broken off hair tips



Figure 2. Dog hairs - middle and tip fracture of hair shaft



Figure 3. Dog hairs - fractured hair shaft



Figure 4. Kitten hairs - unusual shaped hairs in pili torti (genetic defect)

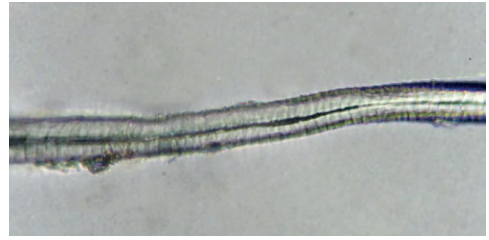

Figure 5. Dog hair - unusual shaped hairs in hepatocutaneous syndrome (metabolic defect)

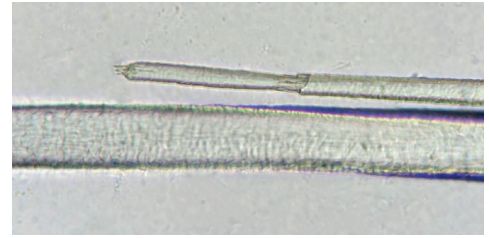


Figure 6. Dog hairs - loss of cuticle and cortex integrity in hepatocutaneous syndrome (metabolic defect)



Figure 7. Dog hairs - diffuse cuticle defects

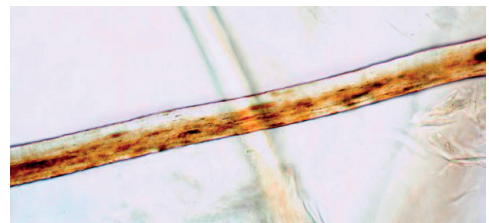


Figure 8. Dog hairs - pigmentary abnormality (melanine clumping)



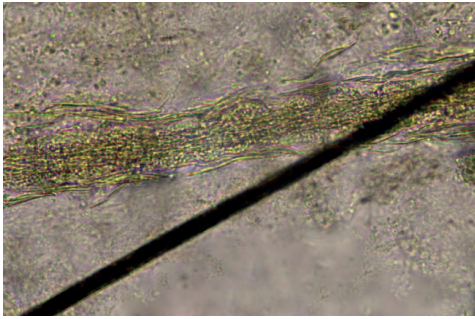


Figure 9. Cat hairs - severe damage of hair shaft structure: hyphae and spores (dermatophytosis)

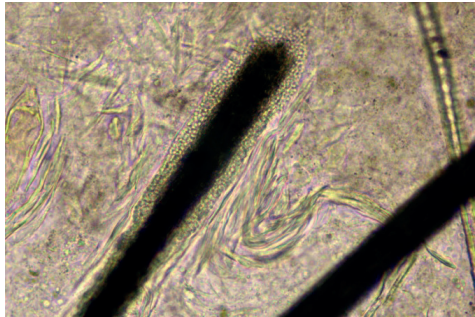


Figure 10. Cat hairs - sleeves of microspores around hair shaft (dermatophytosis)

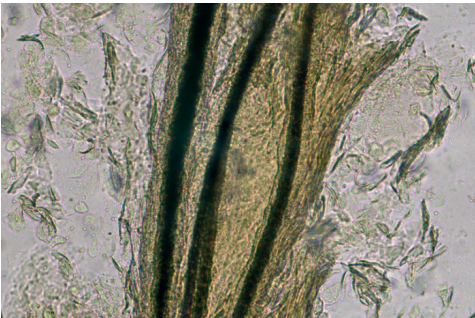


Figure 11. Cat hairs - large hair castings (dermatophytosis)



Figure 12. Dog hair - one adult of *Demodex* mite hanging on the hair bulb in anagen phase

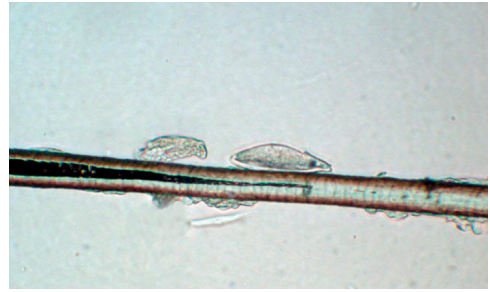


Figure 13. Dog hair - a spindle shaped egg of *Demodex* mite attached to hair shaft



Figure 14. Buffalo hairs - an egg of *Chorioptes* mite attached to hair shaft



Figure 15 Buffalo hairs - an operculated louse egg (*Haematopinus* spp.) cemented to hair shaft



Figure 16. Buffalo hair - an adult of *Chorioptes* mite attached to hair shaft and hair casting

## CONCLUSIONS

Acquired alopecia was of higher frequency compared to congenital alopecia. The present study emphasized the valuable aid of trichogram in definitive diagnostic of parasitic and dermatophytosis - induced alopecia. Trichogram was also indicative for self-induced alopecia (in pruritic conditions), keratinization and pigmentary disorders of various origins.

## REFERENCES

- Butler, J.F. (1985). Lice affecting livestock. In: Williams, R.E., Hall, R.D., Broce, A.B., Scholl, P.J. (Eds.), *Livestock Entomology*. Wiley, New York, 101–127.
- Colombo, S., Cornegliani, L., Beccati, M. et al. (2010). Comparison of two sampling methods for microscopic examination of hair shafts in feline and canine dermatophytosis. *Veterinaria (Cremona)*, 24, 27–33.
- Geary, M.R., & Baker, K.P. (1986). The occurrence of pili torti in a litter of kittens in England. *JSAP*, 27(2), 85–88.
- Guaguère, E., Prélaud, P., Craig, M. (2008). *A Practical Guide to Canine Dermatology*. Kallianxis, Italy.
- Medleau, L., Hnilica, K.A. (2006). *Small Animal Dermatology, a Color Atlas and Therapeutic Guide*. Saunders Elsevier, Missouri.
- Moriello, K.A., & Mason, I.S. (1995). *Handbook of Small Animal Dermatology*. 1st edition. Oxford: Pergamon Press. 23–25 (Hair examination for fungal elements).
- Paterson, S. (2002). An approach to focal alopecia in the dog. *BSAVA Small Animal Dermatology*, 2(4), 77–82.
- Veneziano, V., Rinaldi, L., Giannetto, S., Cringoli, G. (2003). The first record of *Haematopinus tuberculatus* on *Bubalus bubalis* (water buffalo) in Italy. *Bubalus bubalis*, 9: 69–75.