

MORPHOLOGICAL STUDY OF THE THORACIC LIMB JOINTS IN DOGS

**Cristian BELU, Iulian DUMITRESCU, Bogdan GEORGESCU, Petronela Mihaela ROȘU,
Anca ȘEICARU, Ștefania Mariana RAITA, Theodora Raluca ȘTEFĂNESCU,
Sorina Andreea MIHAL, Mădălina DOBRILĂ, Oresti MIHELIS, Gabriel PREDOI**

University of Agronomic Sciences and Veterinary Medicine of Bucharest, Faculty of Veterinary
Medicine, 105 Splaiul Independenței, District 5, Bucharest, Romania

Corresponding author email: cristbelu@yahoo.com

Abstract

Dogs are one of the most morphologically diverse species, as they can range from a 1kg Chihuahua to a 100kg English Mastiff. This morphological diversity affects the appendicular skeleton, leading to a raised incidence of pathologies regarding joints (osteoarthritis, arthrosis, elbow dysplasia). This study was done on 20 dog cadavers. The joints of the forelimb were described in detail. The main purpose was obtaining photographic images which can highlight elements that were previously not mentioned in specialty literature. Following the study, some unique aspects were evidenced such as: dimensions and positioning of glenohumeral ligaments, the topography of the collateral ligaments of the elbow joint and the importance of the proper ligaments of the antebrachial-carpal-metacarpal complex in the dynamic of the movements of this joint. We have compared photographs of the dissected specimens with each other as well as with previously existent sketches from different authors who have tackled the same subject in the past, and we have conclusively pointed out the elements which we considered useful to those interested in resolving pathologies of the locomotor apparatus in carnivores.

Key words: dogs, joints, tendon, skeleton.

INTRODUCTION

Canids (Canidae) represent a family of semi-digitigrade, small and middle sized carnivorous mammals, spread all around the globe. The most well-known representatives of this family are: wolves, foxes, jackals, coyotes and various species of wild dogs, as well as the domestic dog.

These animals are small or middle sized, with a corporeal mass which varies from 1 to 75 kg, depending on the species. In general males are larger than females. Canids have tall, long, relatively thin legs, ending in small paws. The anterior limbs usually have five, rarely four fingers, and the posterior limbs always have four fingers with non-retractable, thick and blunt claws. (Wang & Tedford, 2007; Predoi et al., 2020).

General morphological characteristics of the limbs, presented above, make the species in the canid family good and resistant runners and swimmers (Hermanson et al., 2019; König & Liebich, 2015; Predoi et al., 2020). They catch their prey after chasing it for a long time, moving at a constant pace, in a gait or gallop.

Just as in wild species, the domestic dog kept the general conformation and structure of the limb joints. However, in time, human intervention on genetic structure led to obtaining a multitude of breeds, expressing through an extraordinary phenotypic diversity. In some cases, the dynamic performances of the animals vastly improved. Thus, greyhounds and other sighthounds are capable of speeds far superior to most wild canids. Unfortunately, genetic selection had, in other cases, a negative side. Breeds were created who were shrunken in size considerably, significantly modifying the morphology of the bones of the limbs, affecting the rapports between them, and in turn, the conformation of the joints (Serpell & Duffy, 2014; Tarafder & Lee, 2016).

The importance of this research is strongly connected to its practical application, namely orthopaedic surgery (interventions such as osteosynthesis, repairing fractures, luxations, etc.) (Stone, 1985; Zhang et al., 2015). A second reason is the wish to complete existing literature data with a series of images, taken directly from the dissected pieces which can be useful to those interested in the subject, both

from the veterinary medicine domain as well as experimental medicine.

MATERIALS AND METHODS

The study material was represented by limbs originating from eight dog bodies. After skinning, the anterior limbs were detached by sectioning the connecting muscles between the scapula and the torso, and then the basin with the posterior limbs, through a section in the caudal lumbar region, before the iliac wing.

The peri-articular musculature was carefully removed, initially maintaining the integrity of the articular capsules. Connective means were dissected through classical methods, and after the description and photographing of these structures, the capsular ligament was removed, dissecting the proper or intracapsular ligaments, when necessary.

The more suggestive images were photographed and edited on the computer in the Adobe Photosop C3 program.

The description and homologation of these structures and formations was done in accordance with *Nomina Anatomica Veterinaria* - 2017.

RESULTS AND DISCUSSIONS

The scapulohumeral joint is a spheroidal joint between the glenoid cavity of the scapula and the humeral head. This joint allows all types of movements, but mainly flexion and extension. A glenoidal labrum approximately 1-2 mm thick, disposed on the exterior of the edge, caudolaterally, extends the surface and the profoundness of the scapular glenoid cavity. The articular capsule forms a thin sleeve, attached proximally to the glenoidal labrum (Figures 1 and 2).

The distal insertion of the capsule is a few millimetres distally from the articular surface of the humeral head, where the continuity with the periosteum of the humeral neck can be observed. A portion of the articular capsule surrounds the origin tendon of the brachial biceps muscle, extending distally approximately 2 cm in the intertubercular groove. Its tendon and its synovial sheath are maintained in the intertubercular groove by the transverse humeral ligament.

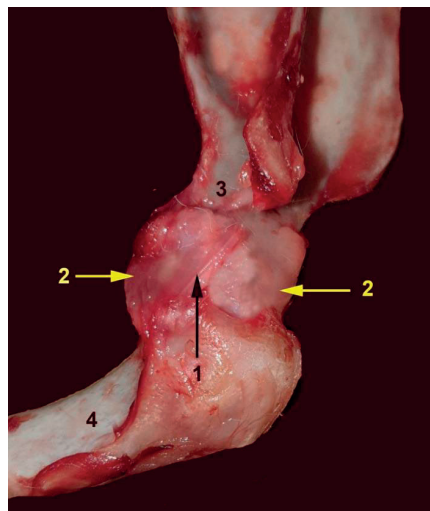


Figure 1. Right scapula-humeral joint - lateral view (original)

1 - lateral glenohumeral ligament; 2 - articular capsule; 3 - scapular neck; 4 - humerus

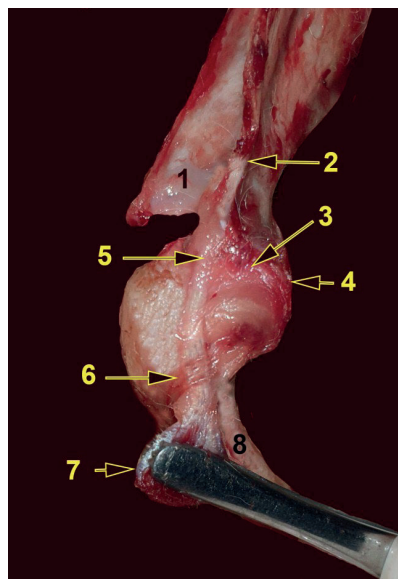


Figure 2. Right scapula-humeral joint - cranial view (original)

1 - spina scapularis; 2 - supraglenoidal tuberosity; 3 - articular capsule; 4 - medial glenohumeral ligament; 5 - tendon of the biceps muscle; 6 - transverse humeral ligament; 7 - biceps muscle; 8 - humerus

The capsule unites with this ligament cranio-medially, and in the medial side with the tendon of the subscapular muscle. In the lateral side, the capsule unites with the tendons of the supraspinatus and infraspinatus muscles. In

other areas, especially caudally, the articular capsule is thin. Medially and laterally, the fibrous of the capsule is thickened, forming the lateral and medial glenohumeral ligaments. The strong tendons adjacent to the joint can be considered active ligaments. These ensure the integrity of the joint, making shoulder dislocations at this species almost impossible.

The humero-radio-ulnar (elbow) joint is a compound joint, made from the articulation of the humeral condyle with the head of the radius on one hand – the humeroradial joint – and of the latter with the semilunar notch of the ulna on the other hand. The proximal radioulnar joint has a cavity which widely communicates with the synovia of the other joints, being considered part of the elbow joint. The humeroradial joint is the joint which makes the anterior limb support the largest part of the body weight.

The humeroradial joint stabilises and restricts movements to flexion and extension of the forearm, while the proximal radioulnar joint allows the rotation movement of the forearm. Lateral movements of the articular complex are minimal, due to the strong collateral ligaments but also due to the anconeal process being profoundly inserted in the olecranon fossa of the humerus. Adding up the rotation movements allowed by the proximal radioulnar joint with the ones allowed by the carpal articular complex, permits a supination of the autopodium of approximately 90°.

There is an articular capsule common to these three joints. In the cranial side, or the flexor side, it inserts proximally to the supratrochlear foramen, including the radial fossa almost in its entirety. In the caudal side, or the extensor side, the articular capsule forms a synovial bursa covered in adipose tissue, attaching distally to the supratrochlear foramen, so that the anterior cavity does not communicate through this foramen with the posterior one. For the most part, but especially in the cranial side, the synovial membrane attaches intimately to the articular cartilage. Medially, a synovial bursa is sent under the brachial biceps muscle and another similar one appears laterally, under the carporadial extensor muscle and the common digital extensor muscle. On the caudo-medial side there is an extension of the synovial, under

the carporadial flexor muscle and the humeral portion of the profound digital flexor.

The lateral collateral ligament inserts proximally on the lateral epicondyle of the humerus. Distally it divides, and the cranial fascicle which is somewhat thicker attaches to a small eminence distally under the neck of the radius. The other fascicle, flatter, passes on the ulna (Figure 3).

At the level of the circumference of the joint, the collateral ligament is interwoven with the annular ligament (Figure 5).

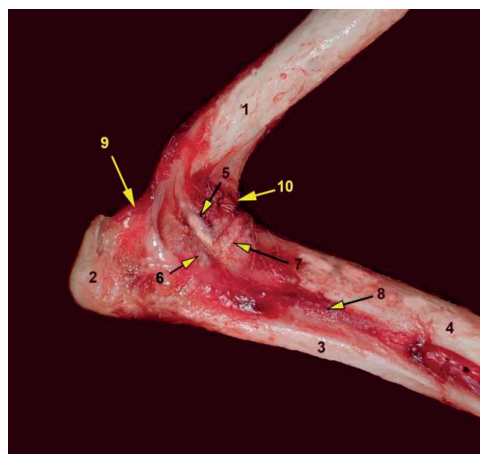


Figure 3. Right humero-radial-ulnar joint – lateral view (original):

- 1 - humerus; 2 - olecranon; 3 - ulna; 4 - radius;
- 5 - collateral lateral ligament - radial fascicle;
- 6 - collateral lateral ligament - ulnar fascicle; 7 - annular ligament (ring); 8 - interosseous membrane; 9 - anconeum ligament; 10 - anterior recess of the synovial membrane

The medial collateral ligament is more reduced than its ulnar counterpart, though similar. It attaches proximally to the medial epicondyle of the humerus, crossing the annular ligament distally and dividing it into two fascicles. The more weakly represented one, the cranial one, inserts proximally to the radial tuberosity. The caudal one, stronger, enters the interosseous space profoundly, where it attaches mostly on the ulna but also on the radius.

The annular ligament of the radius is a thin band which surrounds the proximal extremity of the radius (Fig. 4). It inserts on the lateral and medial extremities of the radial notch of the ulna. It is located profoundly from the collateral ligaments, interweaving with the

lateral one. Alongside the ulna, it forms a ring inside of which the radial head twists, thus rotating the forearm.

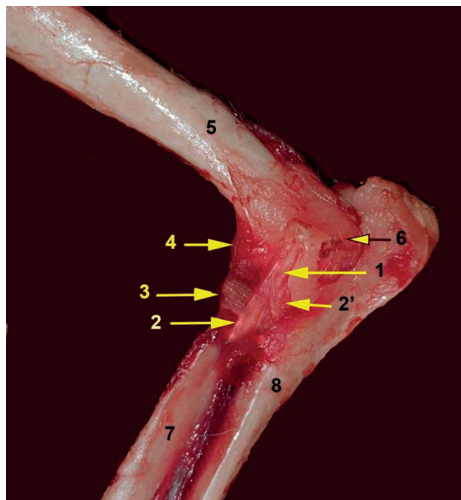


Figure 4. The humero-radial-ulnar joint - medial view (original):
1 - medial collateral ligament; 2 - radial fascicle; 2' - ulnar fascicle; 3 - annular ligament; 4 - dorsal capsular membrane; 5 - humerus; 6 - medial epicondyle; 7 - radius; 8 - ulna

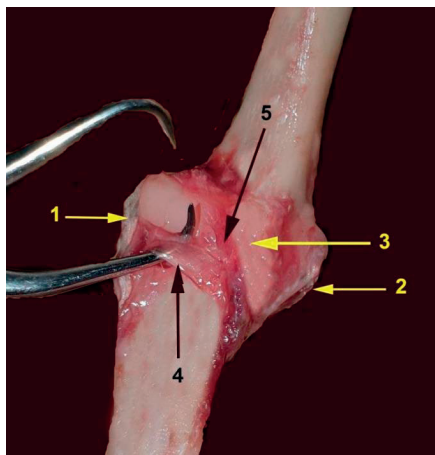


Figure 5. Humero-radio-ulnar joint - cranial view (original):
1 - collateral lateral ligament; 2 - collateral medial ligament; 3 - dorsal capsular ligament; 4 - annular ligament; 5 - oblique strengthening of the articular capsule

The oblique ligament inserts on the dorsal margin of the supratrochlear foramen. It crosses the flexor surface disto-medially, towards the tendons of the brachial biceps muscle and the

brachial muscle. Once it reaches the level of the tendons it divides. The shorter portion fixes itself to the radial collateral ligament. The longer portion ends on the medial side of the radius once it forms a loop around the tendons of the aforementioned muscles.

The radius and the ulna are united through synovial joints at the extremities and through a powerful interosseous ligament completed by the interosseous membrane of the forearm.

The proximal radio-ulnar joint (already mentioned as part of the elbow joint) is a joint between the articular circumference of the radius and the radial notch of the ulna, with a depth of approximately 5 mm (Figure 6).

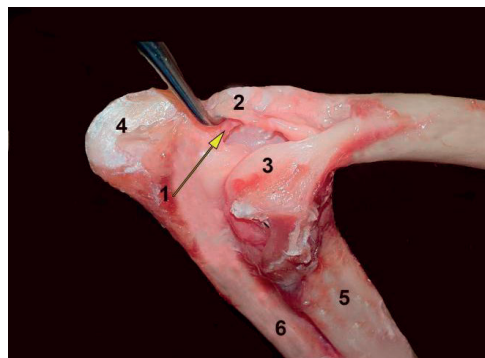


Figure 6. Right humero-radio-ulnar joint - caudo-lateral view (original):
1 - elastic ligament; 2 - medial epicondyle; 3 - lateral epicondyle; 4 - olecranon; 5 - radius; 6 - ulna

The interosseous ligament of the forearm is a short but strong ligament, which passes over the interosseous space, between two rugged lines belonging to the two bones. Its medium sizes are: 2 cm long, 0.5 cm wide and 0.2 cm thick. It is located in the middle portion of the two bones.

The interosseous membrane of the forearm is a narrow and thin septum which connects the radius and the ulna, both above and below the interosseous ligament. It interposes between the osseous margins of the radius and ulna. The membrane extends from the proximal and distal radioulnar synovial. Proximally it is perforated by the passage of the common interosseous artery and vein, as well as the interosseous nerve. Distally, a reduced perforation in the membrane allows the passage of the dorsal distal interosseous artery and vein from the palmar side to the dorsal side.

The distal radioulnar joint is between the distal extremities of the two bones, the ulna having a slight articular convexity and the radius a weak concavity. The capsular ligament in this case is represented by the distal portion of the interosseous membrane.

The **antebrachial-carpal-metacarpal** articular complex is an intricate joint. The antebrachial-carpal articulation is localised between the distal extremities of the radius and ulna and the proximal row of carpal bones. The middle carpal joint is between the two rows of carpal bones. The carpo-metacarpal joints are located between the carpus and metacarpus. The joints between the carpal bones of the same row are called intercarpal joints. The articular complex in its entirety functions as a ginglymus, allowing flexion, extension and slight lateral movements. The more ample movements are permitted by the antebrachial-carpal joint and middle carpal joint. The intercarpal joints and carpal-metacarpal joints allow more reduced movements.

There are no continuous collateral ligaments between the three major articulations of the complex (Figures 7 and 8).

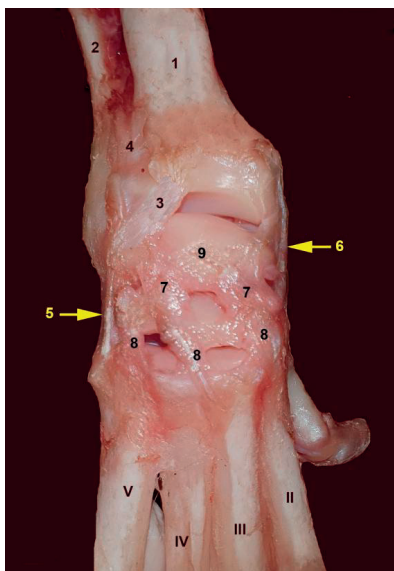


Figure 7. Antebrachial-carpal-metacarpal joint (right limb) - dorsal view (original):

1 - radius; 2 - ulna; 3 - radio-carpal dorsal joint; 4 - radio-ulnar dorsal ligament; 5 - collateral lateral ligament; 6 - collateral medial ligament; 7 - dorsal medio-carpal ligaments; 8 - dorsal carpo-metacarpal ligaments; 9 - scapho-lunar bone; II-V - metacarpals

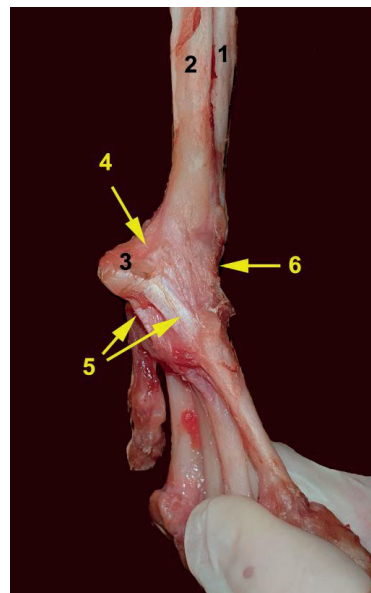


Figure 8. Autopodium joints in dog - lateral view (original):

1 - radius; 2 - ulna; 3 - pisiform; 4 - pisi-ulnar ligament; 5 - pisi-metacarpal ligaments; 6 - capsular dorsal ligament

The dorsal and palmar sides of the articular capsule are far thicker than in the case of other joints specialised in flexion and extension. The long collateral ligaments are absent. The integrity of the joint is ensured by two sleeves of connective tissue, with tendons in-between. The superficial sleeve is formed through a modification of the profound carpal fascia, while the profound sleeve is practically the fibrous component of the articular capsule (the capsular ligament).

The transverse palmar carpal ligament is a modification of the carpal fascia. It inserts laterally on the medial side of the base of the pisiform bone and widens medially, in order to insert on the styloid process of the radius and on the prominences of the most medial carpal bones. The superficial transverse palmar carpal ligament is divided in two layers. One is disposed superficially and another between the tendons of the superficial and profound flexor muscles. The carpal canal on the palmar side of the carpus is represented by the space between the superficial sheet of the transverse palmar carpal ligament, which represents the superficial wall of the canal and the palmar portion of the articular capsule, which

represents the profound wall. It includes tendons and synovial sheaths of the superficial digital flexor and profound digital flexor muscles, the radial, ulnar, palmar interosseous arteries and veins as well as the medial and ulnar nerves.

The palmar carpal fibrocartilage (carpal shield) (Figure 9) crosses the palmar surface of the carpal bones, treading on all of them except the pisiform bone. The fibrocartilage is thickened distally, this area inserting on the distal row of carpal bones and on the adjacent surfaces of the proximal portions of the III, IV and V metacarpals. The palmar carpal fibrocartilage serves as an origin to the special muscles for the II and V finger, and partially as an origin of the interosseous muscles. It levels the palmar irregularities of the carpal-metacarpal joints, smoothing the anterior wall of the carpal canal. A series of reduced ligaments were also observed.

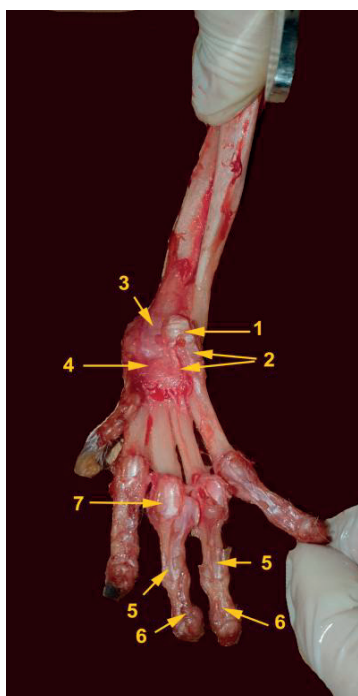


Figure 9. Autopodium joints in dog - palmar view:
1 - pisiform; 2 - pisi-metacarpal ligaments; 3 - palmar radio-carpal ligament; 4 - carpal shield; 5 - insertion of the superficial flexor muscle; 6 - insertion of the profound flexor muscle; 7 - greater sesamoids

Thus the short medial collateral ligament is represented by a straight portion and an oblique

portion. The straight portion detaches from a tubercle situated above the styloid process and reaches the medial side of the carpal-radial bone (scafo-lunar bone). The oblique portion, once it detaches from the styloid process, orients towards the palmar-medial surface of the same bone. In its trajectory on the medial side of the main carpus, the tendon of the *abductor pollicis longus* muscle passes between the two portions.

The intermetacarpal joints are tight connections between the proximal extremities of adjacent metacarpal bones. The synovial membrane of the adjacent carpo-metacarpal joint inserts itself for a few millimetres between the metacarpal bones. Distal to the synovial are the bones are united on variable distances through fibrous tissue, which forms the interosseous metacarpal ligaments. Distal to these ligaments are the interosseous spaces of the metacarpals.

The metacarpo-phalangeal joints are five in number. They are formed with the participation of the distal extremities of the metacarpal bones and the proximal extremities of the phalanges. Each main finger also has two palmar sesamoids. Each joint has its own capsule with two collateral ligaments. Each pair of palmar sesamoids is united through an intersesamoid ligament. This short cartilaginous ligament is represented by transverse fibres which unite the sesamoids and cover their palmar side.

The lateral and medial sesamoid ligaments are represented by short, flattened fascicles, located on each side of the joint. A first portion of the ligament inserts on the corresponding surfaces, lateral and medial, of the sesamoid bones, and then on the distal surfaces of the metacarpal bone, caudal to the proximal insertion of the collateral ligaments. A second portion orients towards the lateral and medial tubercles of the proximal phalanx. From the distal extremity of each pair of sesamoids there is a thin fascicle which attaches to the palmar side of the proximal phalanx. This is called the distal sesamoid ligament. The crossed ligaments of the sesamoid bones extend from the base of the sesamoids diagonally, to the opposite tubercle from the extremity of the proximal phalanges. In the first finger, usually, there is one sesamoid bone and thus a single ligament.

The dorsal sesamoid bones of the metacarpo-phalangeal joints are fixed through delicate

fibres to the tendon of the common digital extensor muscle and to the interosseous muscles in the proximal side, while distally, through a ligament, they are fixed to the dorsal surface of the middle phalanx.

The proximal interphalangeal joints are formed by the ends of the proximal phalanges, articulated with the fossae of the middle phalanges of the II-V fingers (Figure 9). These are “saddle” type joints. The dorsal wall of each articular capsule is thickened by a cartilaginous nucleus. The tendons of the extensors are intimately united with the capsules, which is why the cartilaginous sesamoids appear to be included in these. In the palmar area the articular capsules are intimately fused to the tendons of the flexors.

The collateral ligaments are represented by strong collagen fascicles, which are not parallel to the finger axis, but disposed vertically. They insert proximally in the fossae on the lateral sides of the distal extremities of the phalanges, and distally on the collateral tubercles of the proximal middle phalanges. At the I finger, which only has two phalanges, the collateral ligaments insert distally on the proximal extremity of the distal phalanx.

The distal interphalangeal joints, from the II to the V finger are formed by the ends of the middle phalanges articulated to the fossae of the proximal extremities of the distal phalanges. On the palmar side of the articular capsule a single cartilaginous sesamoid can be encountered; it is small and spheroidal. On the lateral sides there are thickened areas, the collateral ligaments, which insert proximally in the fossae disposed on each side of head of the middle phalanx and extend obliquely caudo-distally in order to attach on the lateral sides of the ungual crest of the distal phalanx. The dorsal ligaments are represented by two elastic chords which traverse the dorsal part of the distal interphalangeal joint, a short distance away from it. The proximal insertion is on the middle phalanx, 2 mm away from one another. It approaches distally, inserting on the dorsal side of the ungual crest. Thus the retraction of the claw is maintained passively, so that it does not reach the ground unless in the case of the contraction of the profound digital flexor muscle.

CONCLUSIONS

In the case of the scapulohumeral joint, the articular capsule though relatively thin, is consolidated both by lateral condensations (glenohumeral ligaments), as well as strong tendons, adjacent to the joint which can be considered active ligaments.

Although it allows a supination of the autopodium of approximately 90°, the elbow joint is consolidated on the lateral sides by powerful collateral ligaments. In spite of these not being able to allow “resort type” movements to the joint (like it does in equines), there is an elastic radioulnar ligament which has great importance in the passive extension of this joint.

The collateral ligaments of the antebrachial-carpal-metacarpal complex are more reduced than in herbivores. No continuous ligaments can be observed in this complex. However, there is a consolidation of the dorsal ligaments in this region, with both dorsal radiocarpal ligaments and dorsal mediocarpal ligaments encountered.

Two pisi-metacarpal ligaments can be observed: one fixed on the V metacarpal and one on the proximal extremity of the IV metacarpal. The palmar carpal shield can be confused for the majority of the proper palmar ligaments.

REFERENCES

- Hermanson, J.W., Evans, H.E., deLahunta A. (2019). *Miller's Anatomy of the Dog*. 5th ed. Philadelphia, PA: Saunders.
- König, H.E., Liebich, H., (2015). *Veterinary Anatomy of Domestic Mammals*. Textbook and Colour Atlas – 6a ed. Stuttgart, Schattauer.
- Predoi, G., Georgescu, B., Belu, C., Roșu, Petronela, Dumitrescu, I., Șeicaru, Anca (2020). *Anatomia animalelor domestice – Osteologie, Artrologie, Miologie* – Editie adăugită și revizuită - Ex Terra Aurum.
- Serpell, J., Duffy, D. (2014). Dog Breeds and Their Behavior, In book: *Domestic Dog Cognition and Behavior* (pp.31-57) Edition: 1st Chapter: *Dog Breeds and Their Behavior* Publisher: Springer Editors: A. Horowitz
- Stone, E.A. (1985). *Textbook of Small Animal Surgery*. 2nd edn. Ed D. Slatter. Philadelphia, W. B. Saunders.
- Tarafder, S., Lee, C.H. (2016). Chapter 14 – Synovial Joint: In *Situ Regeneration of Osteochondral and Fibrocartilaginous Tissues* by Homing of

- Endogenous Cells, In Situ Tissue Regeneration, Academic Press, Pages 253-273
- Zhang, X., Blalock, D., Wang J., (2015). *Classifications and Definitions of Normal Joints, Osteoarthritis - Progress in Basic Research and Treatment*, Qian Chen, IntechOpen.
- Wang, X., Tedford, R. (2007). *Evolutionary history of canids*, in Jensen, P. - *The behavioural biology of dogs*, Cromwell Press, Trowbridge, U.K..